

Title: INFLUENCE OF NEUROSTIMULATION IN A TRANSECTED MEDIAL COLLATERAL LIGAMENT IN SHEEP

Authors: Bill Walsh PhD, Rema Oliver PhD, Ikram Nizam, Dave Bell, Frank Vizesi, Yan Yu PhD, Greg Mitchell, John Rawlinson

Introduction:

Managing pain following surgery is of primary importance in humans as well as animals. Pharmaceutical analgesics or anti-inflammatories have been successfully used for decades to minimise and/or control pain following surgery but have the potential to interfere with the healing process. The current study examined the role of a hand held neurostimulation device on ligament healing in a transected medial collateral ligament (MCL) model in sheep. Our null hypothesis was that the neurostimulation would have no effect on ligament healing.

Methods:

Sixteen adult cross bred wethers were used following institutional ethical approval. Animals were randomly allocated to control or treatment groups (N = 4 at 1 week and N = 12 at 4 weeks). A small incision was made over the patella and skin retracted to expose the medial collateral ligament (MCL). The MCL was transected using a # 15 blade and the wound was closed in layers. Only the right limbs were operated. Assessment of the animal's behaviour, ability to ambulate, swelling at the surgical site and overall demeanour was performed daily prior to treatment as described below.

Neurostimulation was performed over the surgical site using an InterX 5000 device (Neuro Resource Group, Plano, TX, USA) for 15 minutes per day for 3 sessions (8 am, 12 pm and 5 pm) during the first week. Treatment was reduced to 2 times per day (8am and 5pm) for the second week. The remaining time periods had 1 treatment per day. All treatments were performed by the same operator.

Endpoints included macroscopic examination, mechanical testing (4 weeks only) and histology of the MCL and skin on the operated and non-operated limbs. Samples for histology were fixed in buffered formalin, paraffin embedded and sectioned on slides. Stained sections were qualitatively assessed in a blinded fashion for healing response. Immunohistochemistry (IHC) was used to examine protein expression of vascular endothelial growth factor (VEGF) and proliferating cell nuclear antigen (PCNA) using standard techniques. Sections were evaluated in a blinded fashion for protein expression at the MCL transection site.

The femur – MCL – tibia at 4 weeks were isolated and tested in tension using an MTS machine at 20 mm per minute until failure. The peak load (N), stiffness (N/mm), energy (Nmm) was determined for the operative and contralateral (intact) sides. The samples were fixed in formalin and processed for histology as noted above. Mechanical data was analysed using a 1 way analysis of variance using SPSS for Windows and a Games-Howell post hoc test.

Results:

Clinically, treated sheep demonstrated a positive response to the treatment with respect to overall pain and comfort levels. Swelling was reduced with the InterX treatment compared to non-treated, control animals at the surgical site versus time. No macroscopic changes to the skin were noted upon sacrifice between groups. Histology of the skin at treatment site was similar to the non-treated control side at 1 and 4 weeks. Histology of the healing MCL site demonstrated a reduction in overall inflammation at 1 week in the InterX treatment compared to the non-treated controls (Figure 1). Tissue organization was noted to be greater in the InterX treatment group compared to non-treated controls at 1 week. The 4 week histology demonstrated similar improvement in tissue organization at the healing site with InterX treatment compared to non-treated controls. VEGF and PCNA protein expression was noted to be qualitative increased at the healing site in the InterX treated group with more positive staining cells.

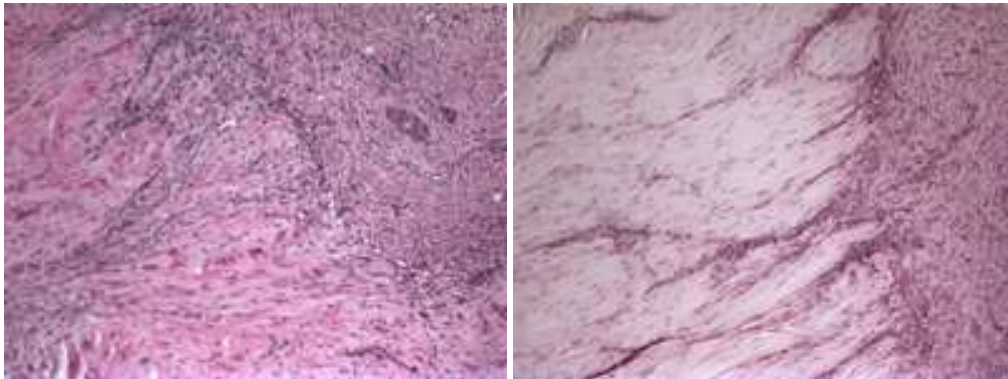


Figure 1. Histology of one week sections of the cutting edges of the ligaments without treatment (left) and with the treatment (right). (Objective magnification 10x)

The histological improvement in organization at 4 weeks however did not result in any statistical improvement in the mechanical properties. InterX treatment had no effect on the tensile properties compared to the non-treated control animals confirming the null hypothesis. All samples failed at the transected site.

Discussion:

A number of neurostimulation methods are used clinically in the treatment of pain [1, 2]. The effect of such devices such as peripheral nerve stimulators on wound healing remains unknown. The current study sought to address the effect of a hand held neurostimulator (InterX 5000) on ligament healing using a sheep model. Clinically, the animals appeared to benefit from the neurostimulation. Swelling at the surgical site was also noted to be reduced with treatment. Mechanically, no adverse or positive effects were observed in MCL healing following neurostimulation as performed in the current study. Histological results however did reveal an overall increase in tissue organization at the healing site along with PCNA and VEGF expression.

This study is limited in the small sample size and short follow up. The InterX device did not have any negative effect on the skin or healing of the transected medial collateral ligament. Histology did however support an improvement in histology at the

healing tissue site compared to controls. The role for such neurostimulator device to provide pain relief following surgery should be explored.

References:

1. Stojanovic, M.P., *Stimulation methods for neuropathic pain control*. Curr Pain Headache Rep, 2001. **5**(2): p. 130-7.
2. Weiner, R.L., *Peripheral nerve neurostimulation*. Neurosurg Clin N Am, 2003. **14**(3): p. 401-8.

www.nrg-unlimited.com